



Case Study: The low FODMAP diet reduced symptoms in a patient with endometriosis and IBS

Erica Jankovich and Alexandra Watkins

Correspondence to: Erica Jankovich, e-mail: erica@eatfitsa.com

© SAJCN

S Afr J Clin Nutr 2017;30(4):32-36

Introduction

Irritable Bowel Syndrome (IBS) and endometriosis are little researched co-morbidities. Symptoms overlap and the lack of a suitable biological marker or a non-invasive diagnostic test, in both cases, make diagnosis complex and confusing.¹ IBS is a gastrointestinal condition diagnosed by the absence of organic disease and the presence of recurrent abdominal pain and alteration in bowel habit.²

Endometriosis is a gynaecological disease with chronic pelvic pain being an overriding symptom.³ Women with endometriosis suffer from severe gastro-intestinal symptoms which mirror those of IBS patients.³ Visceral hypersensitivity is a key feature in both conditions.^{1,4} A diet low in short-chain-fermentable carbohydrates (FODMAPs) has been shown to be a credible dietary treatment for IBS, specifically by reducing visceral hypersensitivity.⁵ It therefore makes sense to test the effect of the low FODMAP diet on patients with endometriosis. Moore et al. recently published a retrospective analysis of the overlap between endometriosis and IBS.⁴ To our knowledge this is the first case report on the use of the low FODMAP diet in a patient with endometriosis and IBS.

IBS and Endometriosis

Endometriosis is a benign, gynaecological disease associated with symptoms of chronic pelvic pain, deep dyspareunia, severe dysmenorrhea, ovulation pain, and dyschezia.¹ Between 15–22% of women with endometriosis are known to have IBS-like symptoms.⁶ In a recent study, 36% of women diagnosed with IBS via the ROME III criteria (Table 1) had concurrent endometriosis.⁴ Histologically 18% of women with endometriosis and gastrointestinal symptoms had bowel lesions.⁶ More than a third of women with endometriosis report worsening of gastrointestinal symptoms at the time of menses when compared with controls.⁶ Over 50% of women with IBS note their symptoms worsen with their cycle.⁶

Table 1: Rome III Diagnostic Criteria* for IBS²

Recurrent abdominal pain or discomfort[†] at least 3 days a month in the past 3 months, associated with two or more of the following:

- Improvement with defecation
- Onset associated with a change in frequency of stool
- Onset associated with a change in form (appearance) of stool

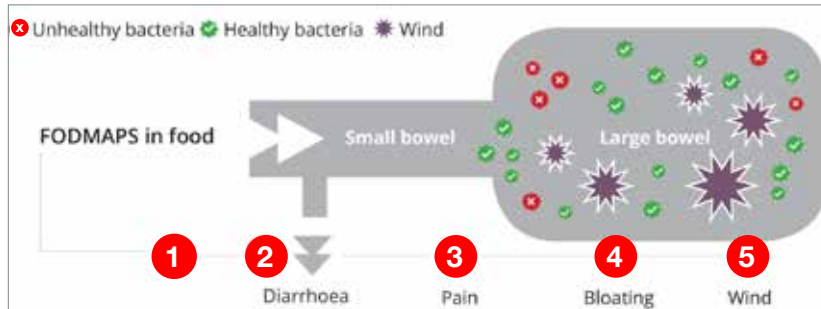
* Criteria fulfilled for the past 3 months with symptom onset of at least 6 months before diagnosis
[†] "Discomfort" means an uncomfortable sensation not described as pain

There is an overlap of symptoms between the two conditions which makes diagnosis difficult. Visceral hypersensitivity, bloating, altered bowel habit, pain on defecation, nausea and a reduced quality of life are common in both conditions.⁴ At the cellular level, mast cell involvement has been implicated in IBS and likewise have been shown to be elevated in endometriotic tissue.⁶

Diet as a treatment for IBS

The role of diet in the management of IBS has been repeatedly reviewed before.⁷⁻⁹ Key scientific bodies have reviewed the latest available data and have made recommendations for health professionals. The American College of Gastroenterology recently updated their guidelines in 2014.¹⁰ The UK based National Institute for Health and Care Excellence (NICE) guidelines for IBS were first published in 2008, updated in 2015 and 2017.⁸ Finally the most recently published British Dietetic Association (BDA) Gastrointestinal Specialist Group (GSG) Position Statement on Dietary Management of IBS was published in 2016.² Most of these guidelines recommend lifestyle modification (relaxation, exercise, stress reduction) and healthy eating guidance as the first line advice.

There is a growing body of research on the effects of individual fermentable short chain carbohydrates on the gastrointestinal tract.⁵ In the last 10 years, evidence has emerged for the restriction of a group of shortchain fermentable carbohydrates which have collectively become known as FODMAPs. This is an acronym



- 1 FODMAPs* enter the small bowel.
- 2 If undigested, due to an enzyme shortage (e.g lactase) or lack of suitable fructose transporter mechanisms.
- 3 FODMAPs cause an osmotic shift in the ileum drawing excess fluid into bowel softening the stool. Triggering visceral hypersensitivity and subsequent pain.
- 4 & 5 Undigested FODMAPs *reach the large bowel where they are fermented by luminal bacteria producing increased methane, hydrogen and carbon dioxide triggering luminal distension, increased pain, wind and bloating. Additional cellular impact - Immune modulation – increased mast cell activation.

Figure 1: Mechanism of action of short-chain fermentable carbohydrates in the bowel⁹

* FODMAPs - Fermentable Oligosaccharides, disaccharides, Monosaccharides and Polyols

developed by Monash University, the pioneers of this treatment, and stands for **F**ermentable **O**ligosaccharides (e.g. wheat, rye, onion, garlic), **D**isaccharides (e.g. milk), **M**onosaccharides (e.g. mango, honey) **A**nd **P**olyols (e.g. xylitol, plums). The common factor in these foods is the size and chain length of these carbohydrate molecules, as they all contain between 1 and 10 glucose molecules. This group of short-chain carbohydrates is susceptible to colonic fermentation by a number of possible mechanisms, which have been shown to exacerbate IBS symptoms.⁵

Mechanisms of action

As shown in Figure 1 there are several mechanisms of action to explain how the malabsorption of FODMAPs contributes to gastrointestinal symptoms.^{5,9}

There is strong evidence to support three mechanisms of action:

1. Augmentation of small intestinal water

Unabsorbed fructose, polyols and lactose in the small bowel lead to an osmotic shift resulting in increased small intestinal water. The resulting luminal distension leads to functional GI symptoms.

2. Increased colonic fermentation

The availability of non-digested and/or non-absorbed short-chain carbohydrates for colonic fermentation leads to accumulation of colonic gas including hydrogen and methane. This is likely to lead to further luminal distension.

3. Immune modulation

Mast cells play a role in different aspects of gastro-intestinal physiology and pathophysiology, particularly in intestinal sensation, motility, secretion, permeability, inflammation and immune modulation.¹¹ A high FODMAP diet results in an increase in luminal histamine which is associated with mast cell degranulation and a heightened immune response.¹²

Moore et al.⁴ have recently published a retrospective analysis of prospectively collected data from women attending an IBS clinic who

were put on a four week low FODMAP diet. Seventy-two percent of those with concurrent endometriosis reported a greater than 50% improvement in bowel function compared to 49% of those with no known endometriosis ($P=0.001$).

Risks of the low FODMAP diet

Despite its clinical effectiveness the low FODMAP diet does present some risks which need to be considered by the health care practitioner. Following a strict low FODMAP elimination diet leads to a reduction in prebiotic content. This has been shown, in various studies, to reduce the gut microbiological content, specifically *Bifidobacteria* species.¹²⁻¹⁴ *Bifidobacteria* are associated with many health benefits such as maintenance of the intestinal mucosal barrier and modulation of the immune system.⁵ Low levels of *Bifidobacteria* have been associated with increased days of pain in both healthy individuals as well as those with IBS.⁵ There is much research still to be done in this area but questions exist whether the effect of the low FODMAP diet on the microbial community has a detrimental effect on colonic health and whether the mucosal barrier is negatively affected with possible immune involvement^{15,12}

Nutrient intake has also been measured on the low FODMAP diet. Studies are small and inconclusive and the only nutrient that seems really at risk is calcium.¹⁵ In a recently completed long term study where patients were followed up for 6 and 18 months following reintroduction of FODMAPs, without additional micronutrient supplementation, no noticeable nutritional shortfalls were reported. This is attributed time and again to the presence of a FODMAP trained dietitian in the research team and the key need for careful dietetic supervision of elimination diets.¹³

Case report

A 23-year-old female student (Ms. A) was referred to the practice for dietary assessment. She had been diagnosed with IBS by her gynaecologist whom she had been seeing for the past two years for

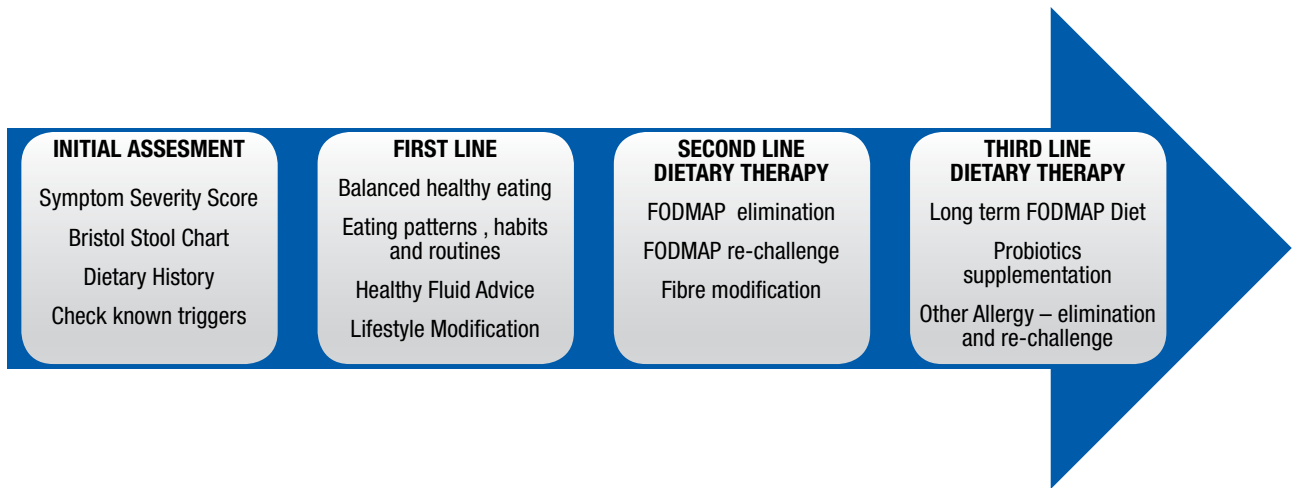


Figure 2: IBS Dietary Treatment Pathway^{2,5,8}

endometriosis. Her clinical assessment by the gynaecologist had eliminated other organic disease. Four months prior to her dietetic appointment, she had been admitted for a laparoscopy to remove the endometriosis from her ovaries. The surgery was uncomplicated and at the time of surgery, it was noted that her colon was compacted. Since the surgery she had continued to complain of lower abdominal pain and other gut symptoms which persist throughout the month but worsen during menses. At first consultation, she was on the following medications; an oral contraceptive, a general multivitamin and aloe vera capsules.

The patient is in her final year of teacher training school. She lives on campus and described herself as 'A-type' personality. She suffered from a measure of anxiety and stress mostly linked to her academic performance and health. She exercised once or twice a day. She relaxed with her friends, going to gym and sleeping.

Anthropometry

Her weight was 60 kg with a height of 1.68 m, her BMI was calculated as 21.3 kg/m². Her weight was stable but she expressed a wish to lose weight and admitted to being very conscious of her weight.

Biochemistry

Her recent full blood count taken a few months earlier was normal. She also had a negative tissue transglutaminase (tTG IgA) blood test indicating absence of coeliac disease. Although she had previously avoided wheat, she reported she had been consuming gluten for the past 6 months prior to the test.

Clinical

On arrival at the dietetic clinic she was asked to complete a 10-point symptom evaluation form developed by the practice and the Bristol Stool Form Chart.¹⁷ She reported her symptom severity as follows; bloating, wind, flatulence, gurgling and constipation were all 8/10, lethargy and abdominal pain 7/10 nausea 6/10. She experienced no urgency, diarrhoea or reflux. Her bowel opened once every 2–3 days with a type 1 or type 2 stool as per the Bristol Stool Form Chart.¹⁷ She reported no history of atopy.

Dietary

The patient had a history of avoiding starchy carbohydrates after having trialed the High Fat Low Carbohydrate diet. She had visited a dietitian 18 months before for assistance with weight loss and at that time she was persuaded to include carbohydrates again in her diet. A detailed diet history was taken. Her overall diet was adequate nutritionally, but lacked planning. She was inclined to miss meals and eat on the go. She would often have a diet shake for breakfast or homemade granola containing seeds, nuts, cocoa and oats. A sandwich or salad for lunch and a cooked meal at night containing meat, chicken and lots of vegetables. She snacked on fruit, seeds, nuts and dried fruit. She drank 3-4 cups of caffeinated fluid and 3000 ml of water a day. Her alcohol intake was in the form of whisky or beer but only when socialising, approximately once a week. She listed her trigger foods as dairy, cauliflower, broccoli, onions and high fat meals.

Medical Management

Ms. A took a regular broad-spectrum multivitamin, a probiotic (containing a prebiotic), an aloe vera supplement to relieve constipation and her contraceptive. The gynaecologist had prescribed an osmotic laxative to be taken as required. No specific dose was prescribed.

Nutritional Management

After clinical and dietary assessment, the dietetic practice follows a 3-step patient management process (see Figure 2). In line with international guidelines, patients must follow first line dietary therapy and lifestyle modification before embarking on second line dietary treatment of the Low FODMAP Diet or fibre modification.^{2,8}

Initial Consultation

Ms. A was advised and counselled to follow first line advice for IBS as per a combination of guidance from NICE (2015)⁸ and BDA (2016),² e.g. regular mealtimes, reduction of fat intake, increased fluid intake and a healthy balanced diet including all the food groups. Ms. A was also given general lifestyle management guidance. She was requested to monitor her symptoms on ingestion of high foods.



She was also asked to complete a detailed food and symptom diary and return it to the dietitian within 2 weeks. She was advised to stop consuming aloe vera capsules due to lack of evidence and given guidance on appropriate laxative usage to aid her constipation. Provided the first line advice did not offer sufficient symptom relief and due to many possible FODMAP triggers in her dietary recall, she was also provisionally added to the next Low FODMAP Group Programme run by the dietetic practice.

Follow Up

Two weeks later Ms. A submitted her diary, she had a more consistent eating pattern and her bowel function had improved. She was now opening her bowel every second day with a type 2 stool (Bristol Stool Form Chart).¹⁷ There was no change in her bloating and her abdominal pain had felt worse at times. The nausea had disappeared and her bowels were little more regular with the use of the laxative combined with the diet (type 3, once every 1–2 days). She had started to make positive lifestyle changes such as better relaxation strategies, less strenuous exercise and better meal planning. Ms. A reported consistent and reproducible symptoms after consuming meals with high lactose content and she felt safer to change to lactose free milk and yoghurt. The dietitian examined her food diary and identified presence of many high FODMAP foods e.g. apples, onions, wheat and garlic. On further discussion Ms. A elected to join the Low FODMAP Group Programme offered by the practice. This was a 16-week elimination and re-challenge programme managed by the practice (2 individual and 2 group meetings throughout the 16 weeks).

FODMAP Group Programme

Ms. A joined the initial 3-hour group training programme, where she received interactive group education to ensure she was able to follow the strict 6-week elimination programme correctly. This includes comprehensive information on implementing the low FODMAP diet into her present healthy eating habits, label and menu reading, recipe adaptation, shopping and much more. She was asked to stop

the probiotic as it contained a prebiotic of fructo-oligosaccharide, which is also a high FODMAP ingredient. She then began the 6-week strict FODMAP elimination programme. This included the elimination of lactose.

At her 3-week individual follow up she reported the Low FODMAP diet was going well. She had managed the substitutes and felt that her symptoms were improving. Her bowel had slowed down a little again to once every 2–3 days. She still had abdominal pain but fewer incidents of pain. She found eating out difficult and asked for help with sauces to add flavour. The dietitians checked her dietary recall and made a few minor changes to ensure nutritional adequacy and helped her with ideas to increase her fibre, regarding eating out and sauce alternatives.

At week 6 she returned for the group re-challenge Session. The 2-hour session instructs the patients how to navigate the difficult challenge phase and provides extra information such as how to supplement with probiotics following the challenges. Finally, they receive some psychosocial education and its role in managing their symptoms. Ms. A completed a further symptom evaluation and we were pleased to see she was much better. She recorded her symptoms as ‘none’ or three out of ten or less. Her bowel opened every second day with the addition of 1 tablespoon of linseeds every morning, she had not used the laxative for a few weeks.

Nutritional Outcome

Ms. A saw a substantial improvement in her gastrointestinal symptoms of bloating, abdominal pain, wind, gurgling, constipation and nausea after first line dietary therapy (see Figure 3). After following the Low FODMAP Diet her symptoms improved further.

Ms. A took 10 weeks to complete the FODMAP reintroduction process. During this time, a dietitian remained in email communication to assist her with her challenges. She returned for her final consultation. Her symptoms were very much under control, her bowel opening every 1–2 days with a type 3 stool.

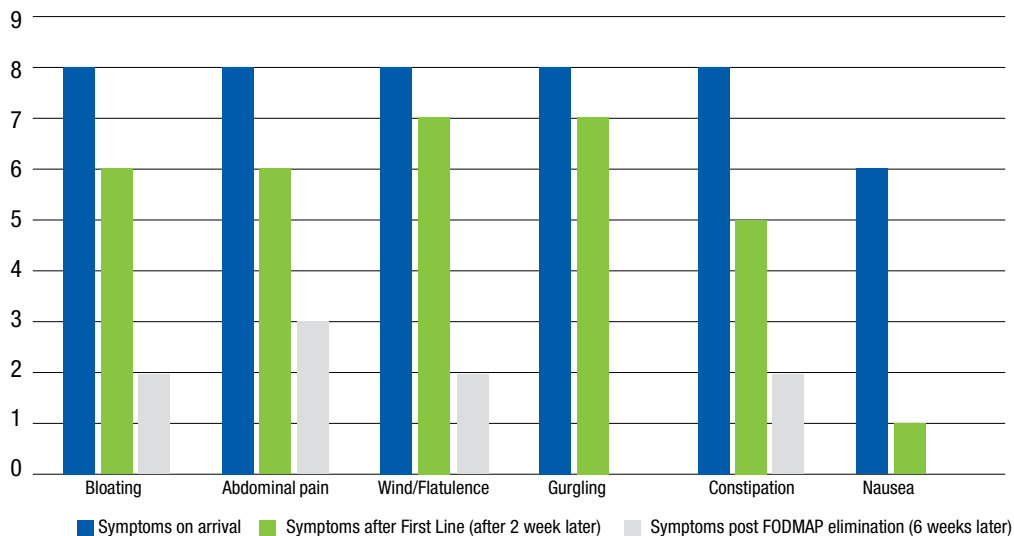


Figure 2: Ms. A - Change in symptom severity throughout the dietary process



Ms. A did not pass the fructose, mannitol or fructan challenges (see Table 2). She did tolerate a small dose of the wheat fructan and the initial dose of the onion fructan group; however, she felt the garlic challenge was not tolerated at all. She received food lists including advice on portion sizes in line with these results. She received further information regarding the modified FODMAP diet going forward and how to test her FODMAP threshold. She was cautioned about the cumulative FODMAP effect and asked to take a 6-week course of a high dose, multistrain probiotic to restore her gut flora.

Table 2: FODMAP Challenge Results

FODMAP CHALLENGE RESULTS		
FODMAP CHALLENGE	TOLERATED	DOSE
Fructose	Minimal	½ Initial dose
Polyols – Sorbitol	Yes	Full dose
Polyols – Mannitol	No	None
Fructans – Wheat group	Minimal	½ Initial dose
Fructans – Onion group	Minimal	Initial dose
Fructan – Garlic group	No	None
Galacto-oligosaccharides	Yes	Full dose
Lactose	Yes	Full dose

A month later she continued to do well, her dietary recall was well balanced with sufficient FODMAP restriction to keep her symptoms under control. She still used the laxative occasionally but reported she always understood what had gone wrong to bring on the constipation. There had been an occasional recurrence of bloating and abdominal pain, but she explained she was now able to trace it back to a particular meal or ingredient. She also understood that diet was not the only trigger for her symptoms and was committed to making further lifestyle changes to reduce her stress levels further.

Discussion

Gastrointestinal symptoms frequently occur in patients with endometriosis whether they have bowel involvement or not.¹⁷ Heightened visceral sensitivity has been documented in both endometriosis and IBS.^{18,19} The low FODMAP diet has been shown to decrease luminal distension and reduce visceral irritation by decreasing excess fluid and gas in the gut.^{5,20}

This case report demonstrates the efficacy of the low FODMAP dietary process in IBS and endometriosis. The interesting result in this particular case is the role of her preconceived ideas with respect to her food intolerances and the strength of the brain-gut involvement. The patient listed dairy as a trigger food at her initial visit, she felt she had failed the home lactose challenge test and therefore avoided dairy for the duration of the programme. When it came to challenging she managed to tolerate the double dose of milk with no symptoms. This is often the case and indeed the dietary process involved in the low FODMAP programme allows the patient to discover their real triggers in a safe, controlled, and logical manner. It empowers the patients, to take control of their condition,

they leave the programme fully understanding the effect of foods on their symptoms.

Conclusion

There is convincing evidence for the clinical efficacy of the low FODMAP diet in IBS.⁵ As confidence in the diet has grown amongst health care practitioners, there are exciting new applications. The overlapping pathophysiology of endometriosis and IBS make it a logical treatment solution. This case study demonstrates that the low FODMAP diet can be effective in reducing symptoms of patients who have endometriosis and IBS.

References

- Seaman HE, Ballard KD, Wright JT, de Vries CS. Endometriosis and its coexistence with irritable bowel syndrome and pelvic inflammatory disease: findings from a national case-control study--Part 2. *BJOG*. 2008;115(11):1392-6.
- McKenzie YA, Bowyer RK, Leach H, Gulia P, Horobin J, O'Sullivan NA, et al. British Dietetic Association systematic review and evidence-based practice guidelines for the dietary management of irritable bowel syndrome in adults (2016 update). *J Hum Nutr Diet*. 2016;29(5):549-75.
- Ek M, Roth B, Ekström P, Valentin L, Bengtsson M, Ohlsson B. Gastrointestinal symptoms among endometriosis patients – A case-cohort study. *BMC Womens Health*. 2015;15:59.
- Moore JS, Gibson PR, Perry RE, Burgell RE. Endometriosis in patients with irritable bowel syndrome: Specific symptomatic and demographic profile, and response to the low FODMAP diet. *Aust N Z J Obstet Gynaecol*. 2017;57(2):201-5.
- Staudacher HM, Whelan K. The low FODMAP diet: recent advances in understanding its mechanisms and efficacy in IBS. *Gut*. 2017;66(8):1517-27.
- Aragon M, Lessey BA. Irritable Bowel Syndrome and Endometriosis: Twins in Disguise. *GHS Proc.*; 2017. p. 43-50.
- Lacy BE. The Science, Evidence, and Practice of Dietary Interventions in Irritable Bowel Syndrome. *Clin Gastroenterol Hepatol*. 2015;13(11):1899-906.
- Diagnosis and management of irritable bowel syndrome in adults in primary care: summary of NICE guidance. *BMJ*. 2015;350:h1216.
- Jankovich E, Watkins AM. Is the restriction of Fermentable Short Chain Carbohydrate (FODMAP) a credible solution for the Irritable Bowel Syndrome patient? *The South African Gastroenterology Review*; 2016. p. 9-17.
- Ford AC, Moayyedi P, Lacy BE, Lembo AJ, Saito YA, Schiller LR, et al. American College of Gastroenterology monograph on the management of irritable bowel syndrome and chronic idiopathic constipation. *Am J Gastroenterol*. 2014;109 (Suppl 1):S2-26; quiz S7.
- Lee KN, Lee OY. The Role of Mast Cells in Irritable Bowel Syndrome. *Gastroenterol Res Pract*. 2016;2016:2031480.
- McIntosh K, Reed DE, Schneider T, Dang F, Keshteli AH, De Palma G, et al. FODMAPs alter symptoms and the metabolome of patients with IBS: a randomised controlled trial. *Gut*. 2017;66(7):1241-51.
- Staudacher HM, Lomer MCE, Farquharson FM, Louis P, Fava F, Franciosi E, et al. Diet Low in FODMAPs Reduces Symptoms in Patients With Irritable Bowel Syndrome and Probiotic Restores Bifidobacterium Species: A Randomized Controlled Trial. *Gastroenterology*. 2017.
- Halmos EP, Christophersen CT, Bird AR, Shepherd SJ, Gibson PR, Muir JG. Diets that differ in their FODMAP content alter the colonic luminal microenvironment. *Gut*. 2015;64(1):93-100.
- O'Keefe M, Jansen C, Martin L, Williams M, Seamark L, Staudacher HM, et al. Long-term impact of the low-FODMAP diet on gastrointestinal symptoms, dietary intake, patient acceptability, and healthcare utilization in irritable bowel syndrome. *Neurogastroenterol Motil*. 2017.
- Maroun P, Cooper MJ, Reid GD, Keirse MJ. Relevance of gastrointestinal symptoms in endometriosis. *Aust N Z J Obstet Gynaecol*. 2009;49(4):411-4.
- Lewis SJ, Heaton KW. Stool form scale as a useful guide to intestinal transit time. *Scand. J. Gastroenterol*. 1997 32(9):920-4.
- Issa B, Wafaee NA, Whorwell PJ. Abdominal bloating and distension: what is the role of the microbiota. *Dig Dis Sci*. 2012;57(1):4-8.
- Spiller R. Irritable bowel syndrome: new insights into symptom mechanisms and advances in treatment. *F1000Res*. 2016;5.
- Halmos EP, Power VA, Shepherd SJ, Gibson PR, Muir JG. A diet low in FODMAPs reduces symptoms of irritable bowel syndrome. *Gastroenterology*. 2014;146(1):67-75.e5.